

Main Session 3:

The Journey to CAR T-Cell Therapy: Practical Considerations and Experiences

INSELSPITAL
UNIVERSITÄTSSPITAL BERN
HOPITAL UNIVERSITAIRE DE BERNE
BERN UNIVERSITY HOSPITAL

Case Presentation

Thomas Pabst

August 27 2020



Center for Hemato-Oncology
UCI UNIVERSITY CANCER CENTER
INSELSPITAL

2012 - Start of CAR-T treatment ...



Start of CAR-T treatment in Switzerland



Jan 09, 2019
Inselspital Bern
...first CAR-T
treatment in CH...
25y, f
rel/ref Phi⁺ ALL

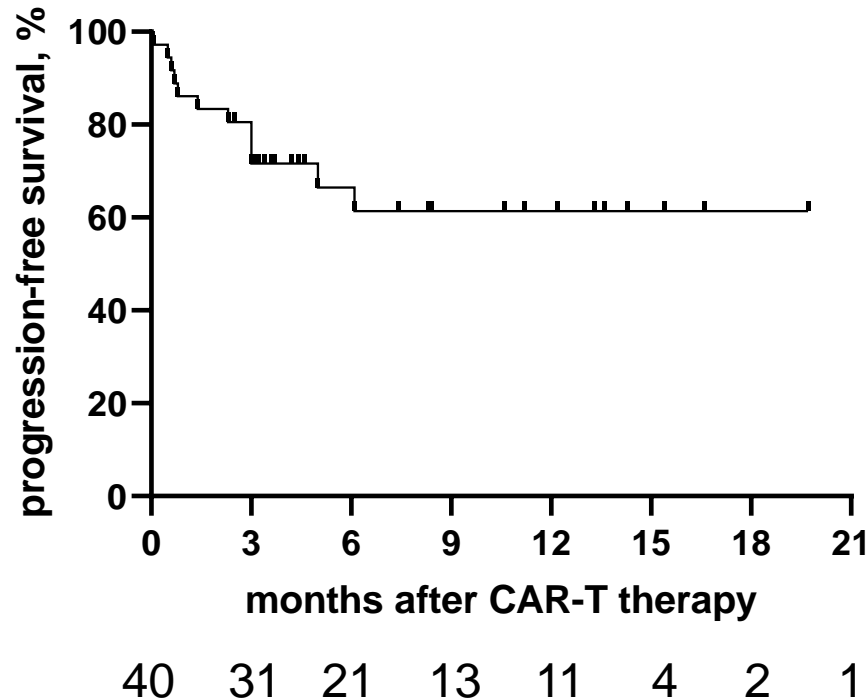
... 07/2020 in ongoing CR

INSELSPITAL
| Universitätsklinik für
Medizinische Onkologie

(with permission of the patient)

Real-world CAR-T results repeat trial findings

PFS

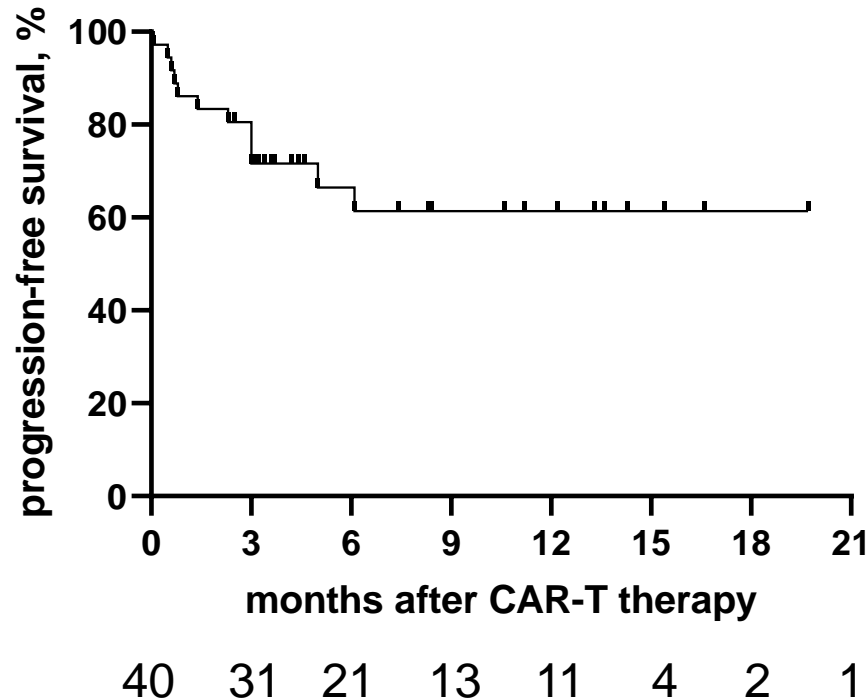


... CAR-T is curative
in r/r DLBCL patients !

CAR-T procedures in Bern
(01/19-07/20)

CAR-T in r/r DLBCL – questions remain

PFS

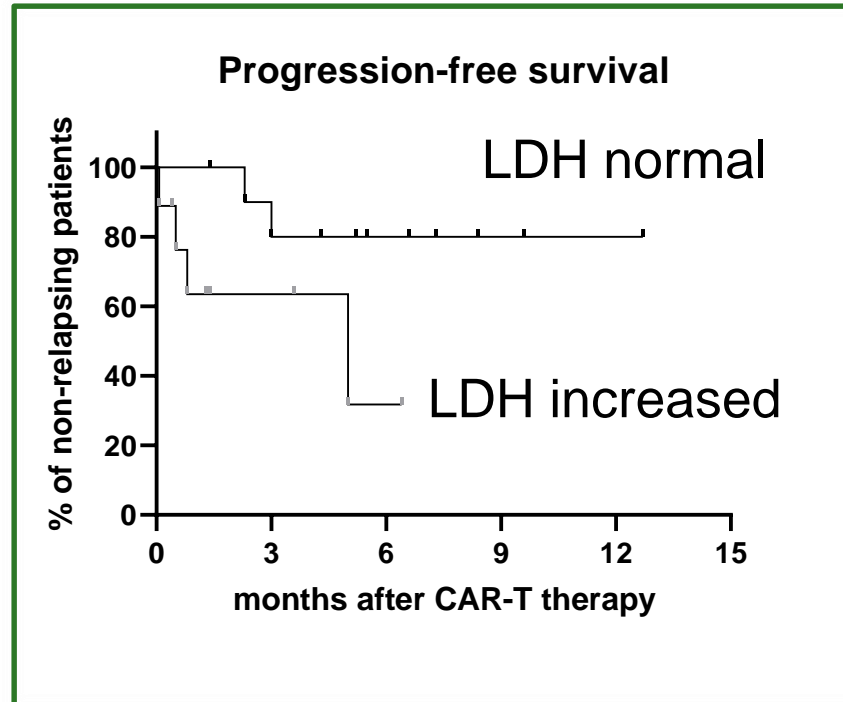


... why is CAR-T failing in some patients ?

CAR-T procedures in Bern
(01/19-07/20)

Patient selection

CAR-T procedures in Bern
(01/19-07/20)



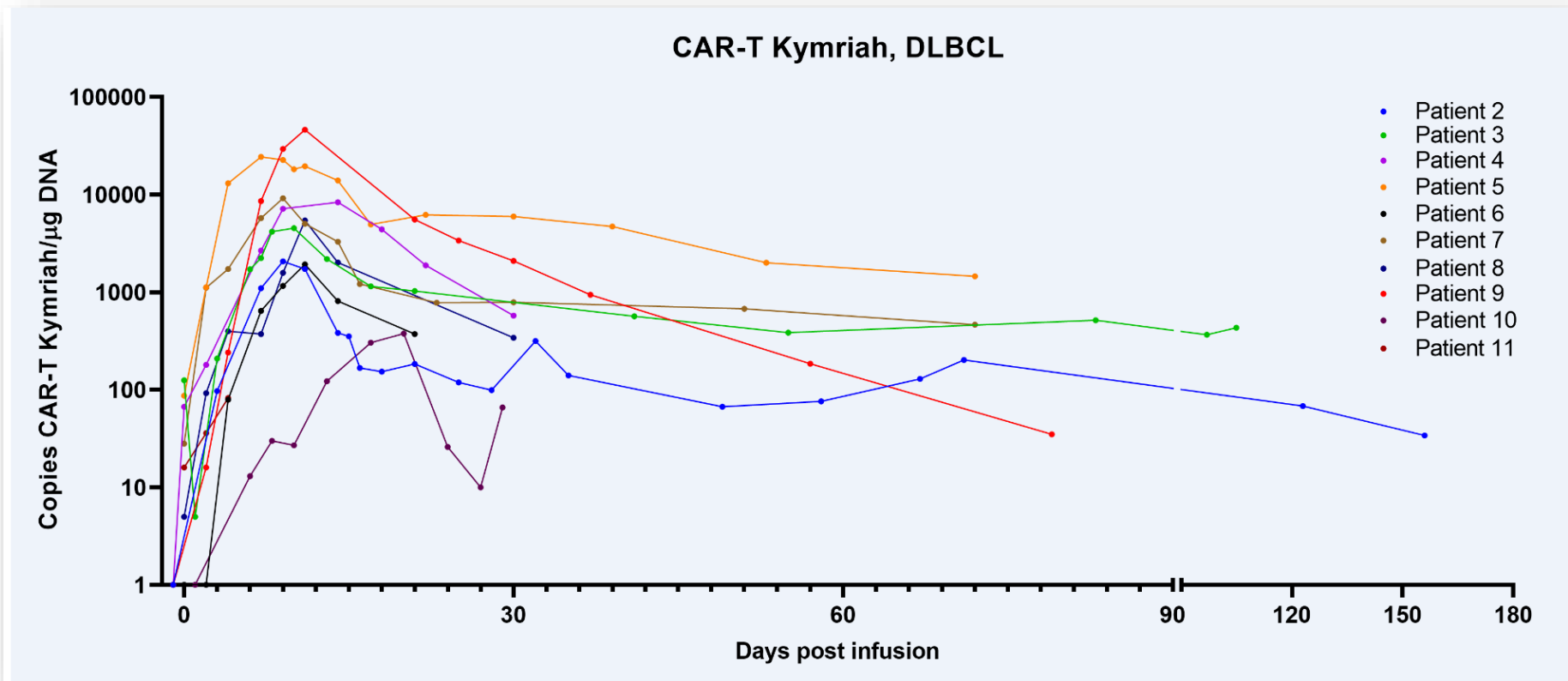
Nydegger *et al*, 2020

... should we omit CAR-T to patients with rapidly proliferating burden disease ?

CAR-T – many questions arising ...

- Kymriah[®] or Yescarta[®] or JCAR (... or trial) ?
- CAR-T and/or autologous transplant in r/r DLBCL ?
- What is the ideal bridging treatment ?
- The issue of long-lasting cytopenias ...
- iv Ig – how long? how often?

CAR-T level patterns in PB by ddPCR: does it matter ?



Radiotherapy & CAR-T treatment

Patient 1

69y; f, rel/ref DLBCL NOS
pelvine bulk (13cm)
radiotherapy after autoSCT
subsequent CAR-T

PET-CT 12 months: CR

Radiotherapy & CAR-T treatment

Patient 1

69y; f, rel/ref DLBCL NOS
pelvine bulk (13cm)
radiotherapy after autoSCT
subsequent CAR-T

PET-CT 12 months: CR

Patient 2

28y; m, rel/ref DLBCL NOS
retroperitoneal lymph. bulk (8cm)
persisting after autoSCT
immediate CAR-T

death due to PD: 1 month

Radiotherapy & CAR-T treatment

Patient 1

69y; f, rel/ref DLBCL NOS
pelvine bulk (13cm)
radiotherapy after autoSCT
subsequent CAR-T

PET-CT 12 months: CR

Patient 2

28y; m, rel/ref DLBCL NOS
retroperitoneal lymph. bulk (8cm)
persisting after autoSCT
immediate CAR-T

death due to PD: 1 month

... a role for radiotherapy in CAR-T ?

CAR-T treatment in r/r DLBCL ...
... has come to stay.